

La rhinoplastie médicale. Etat de l'art

Medical rhinoplasty concept. State of the art

Braccini F.
Fernandez J.
Cegarra-Escolano M.
Kestemont P.
(Nice)¹

Résumé

Le traitement non chirurgical du nez, ou rhinoplastie médicale, est devenu l'une des interventions les plus populaires dans la prise en charge esthétique de la face. L'absence de facteurs mécaniques compressifs (dynamique faciale pauvre dans cette zone anatomique) ainsi qu'une stabilité des supports de la pyramide nasale (os et cartilages) sont favorables aux injections. De ce fait, la durée d'action des fillers au niveau du nez est beaucoup plus importante que dans les autres parties du visage. La satisfaction des patients est optimale lorsque les règles d'usages sont respectées. Les indications de ce traitement médical étaient initialement réservées aux corrections des imperfections post-chirurgicales de la rhinoplastie. Cependant, aujourd'hui, celles-ci sont beaucoup plus étendues notamment en rhinoplastie primaire.

Mots-clés : Rhinoplastie médicale, indication, acide hyaluronique, toxine botulique, fillers.

Summary

Non-surgical nose treatment, or medical rhinoplasty, has become one of the most popular interventions. The absence of high mechanical stresses (facial dynamic rather poor in this area) associated with stability in the supports of the nasal pyramid (cartilages and bones) is really suitable for fillers. Hence, duration of the filling is more important in this place than in other parts of the face. Satisfaction of our patients is much better. Initially, the indications of this treatment were reserved to correct post-surgical imperfections. In fact they are now much more extended and even used in primary rhinoplasty.

Key-words: Medical rhinoplasty, indication, hyaluronic acid, botulinum toxin, fillers.

INTRODUCTION

Rhinoplasty remains above all a procedure for highly-skilled surgeons but the emergence of fillers and botulinum toxin lead us to reevaluate our treatment indications and our advice [1-7]. The goals of the treatment impose an artistic analysis of the nose: We have to consider the nose «by itself» and the nose «in the face», in three dimensions. We will tackle:

❑ The nose in its unity and its proper volumes, which corresponds to nasal volumetry;

❑ The nose in the face and for that we have to consider the global harmony of the face (particularly the nasofrontal angle, nasolabial angle and cheekbones projection).

Contemporary treatment of the lip and the chin with fillers is a way to realize a real medical profile plasty. The treatment of cheekbones, especially their projection, allows us to modify the «relative volumetry of the nose» especially on profile views.

1. HNS & FPS Medical Healthcare, 27 Boulevard Dubouchage, 06000 Nice, France. E-mail: frederic.braccini@gmail.com

Article received: 03/22/16

accepted: 04/19/16

ANATOMICAL BASIS

Anatomical basis are essential to determine the site of the treatment and understand the potential risks related to the injections.

The nose represents the middle third of the face. It is an empty triangular pyramid with an osteochondral structure, where the base is the nostrils and the top corresponds to the nasal root. Over this osteochondral frame lies a perichondrial and periosteal envelope, a muscular layer, and the skin.

We describe (fig. 1):

❑ A fixed part, formed by the bridge of the nose, the rising part of the maxillae, the nasal bones, the upper lateral cartilages (triangular cartilages) and the nasal septum.

❑ A mobile part, represented mainly by the lower lateral cartilages (major and minor alar cartilages) with the lower part of the triangular cartilages, that play a major role in the nasal valve.

Analyzing the relationship between mobile and fixed elements is capital in the treatment plan before a medical or surgical rhinoplasty.

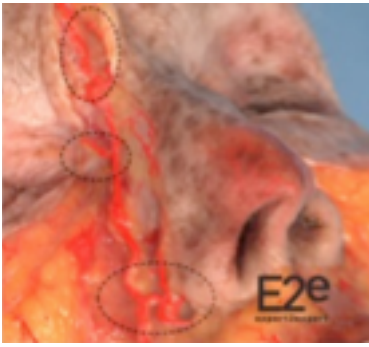

Fig. 1: Anatomical basis.

Practical applications arising from this relationship refer to the morpho-dynamic anatomy concept.

Hyaluronic acid injections are given deeply, in contact with the cartilage or bone structures.

That is to say the knowledge of nasal structure in both soft tissue and nasal frame is crucial before starting a medical rhinoplasty treatment with filler products.

There are various muscles related to the nose: Elevators, depressors, nares compressors or dilators. They play a minor role except for the tip depressor muscle that lowers the nasal tip and increases dorsum kyphosis.

The dilator naris muscles can be active and enlarges the nasal base.

The levator labii superioris alaeque nasi muscle extending throughout the nose length, increases dorsum kyphosis and reduces the nasolabial angle, exposing the superior gingiva («gummy» smile). This muscle, with the nasalis and procerus muscles in the median line, favor the appearance of the «bunny lines».

All these muscles can totally respond to a botulinum toxin action, and shall be selectively disabled as each case may require.

The nose is highly vascularized, with small-sized blood vessels except for the inner canthus region. This vascularization depends on arterial branches from both internal and external carotid arteries, respectively the ophthalmic and facial arteries. Veins drain mostly to the angular vein but to the facial vein as well.

Despite this abundant vascularization there are few risks of hematoma, whereas the major risk lies in vascular embolization, particularly in the nasal ala and glabella.

Tip injections are not harmful if respecting the standard technical precautions.

The motor branches come from the facial nerve, and sensory branches from the trigeminal nerve through infra-orbital and external nasal nerves. Injury of a nerve branch during the procedure has no implications.

INJECTION PRODUCTS

Regarding the thickness of the skin, it is necessary to inject a product with a perfect balance between homogeneity, diffusion potential in the field spaces and safety.

In the case of previous injection with a non resorbable product, any new injection of fillers will be contra-indicated.

There are many fillers available but we gradually turned to hyaluronic acid because it can be injected safely in all the regions; both in the fixed nose area, but also in the nasal tip where the cutaneous tension is very important and where the tolerance of the product is optimal. The product must be highly reticulated so that the result can be stable. It is necessary to use products with full tolerance and safety.

INJECTION TECHNIQUE

Ideally, the intervention should be made after the application of an anesthetic cream over the treated surface. However, it can also be done without any anesthesia. The nasal tip is the most sensitive part. A detailed treatment plan has to be established before starting the injection. Indeed, the nasal cutaneous tension, in particular in the tip area, is so important that if too many injections are made, the product tends to extrude.

Several treatment procedures are described:

In the dorsum area to fill nasofrontal angle and concealing a bump

The needle is introduced with a 45 degree obliquity, up till contact with bone. It is held by the dominant hand. With the thumb and the index fingers of the other hand, it is necessary to press on the lateral walls of the nasal bones so that the product doesn't extend laterally in the mid-face (around the eyes, dark circles, cheek...). Sometimes, it can be useful to fill the nasofrontal angle laterally to achieve a perfect treatment of this region. Once the product is injected, it has to be carefully massaged to spread into place.

Filling a bump in this area is a way to visually «shorten» the length of the nose by increasing the anterior projection of the frontal area. This injection justifies the beneficial effect that we can obtain in «long noses».

Nasal tip definition

We already stressed on the issue of avoiding multiple injection points. Injection pressure is essential. The procedure has to be slow and progressive to avoid a cutaneous injury. The tip shouldn't whiten extensively under the effect of the filling. In our experience of over 650 nasal injection procedures, we have never observed a cutaneous necrosis. The reasons leading to necrosis seem to be embolic in nature.

The face and the nose in particular are very richly vascularized and the vascular collaterals are very numerous. For a cutaneous necrosis to appear, the vascularity has to be «overwhelmed». The risks of embolization are therefore more important with low reticulation products.

For this reason, we recommended using a high concentration, high reticulation product in the nasal area.

Treatment of the columellar region and opening of the nasolabial angle

It can be performed when botulinum toxin treatment is not carried-out in the same sitting. We have to make a direct deep injection of the product in contact with the nasal spine to open the angle. The columellar lines are then balanced more superficially. This procedure can also be achieved with a 27G micro cannula. The use of the cannula is interesting for a dorsum tunneling but not in lateral adjustment or for very fine injections. The needle is still the most common technique.

PROTOCOL OF TREATMENT

No over correction is done on the first procedure. A control follows after two weeks. If deemed necessary, a second injection is realized to improve the result. The outcome will then remain stable for 18-24 months.

INDICATIONS OF MEDICAL RHINOPLASTY

Not all rhinoplasties can be achieved medically! Medical rhinoplasty is a wonderful alternative solution but also a complementary tool for conventional surgery. These two treatment options should not be opposed. The surgeon has to know the benefits and the limits. The indications are given by the artistic analysis and the treatment plan, just as for a surgical rhinoplasty. A computerized morphing can be realized before the treatment.

Augmentation rhinoplasty with reduction of the osteo-cartilaginous kypnosis

This is the best indication of medical rhinoplasty. Indeed, the nasal tip treatment and the filling of the junction with lip and forehead give remarkable results (fig. 2).

After surgical rhinoplasty

Every irregularity (depression of nasal bridge, asymmetry, deviation...) can be filled with a filler (fig. 3). The indications of these fillings are the same as cartilaginous grafts. The injection of a filler following surgical rhinoplasty can be very interesting too. In some cases, adhesences are revealed after the removal of the nasal splint (mobilization of a bone or a cartilaginous fragment). In

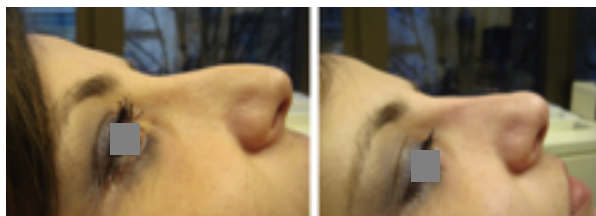

Fig. 2: Medical rhinoplasty. Treatment of the tip with 0,7 cc of hyaluronic acid and botulin toxin in the depressor muscle of the tip.

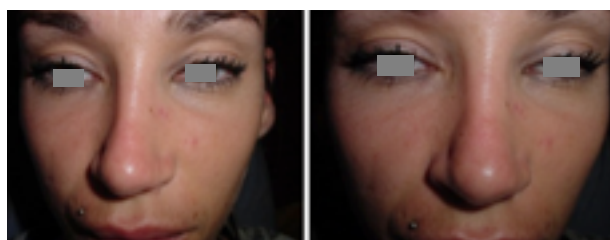

Fig. 3: Medical rhinoplasty. Treatment of a nose deviation with 0,4 cc of hyaluronic acid.

this case, it is very useful to “remove” this adherence with a bolus of hyaluronic acid to avoid a permanent retraction. Fibrosis appears in the filled space after multiples injections, and in many cases this maneuver can avoid a surgical procedure (figs 4, 5).

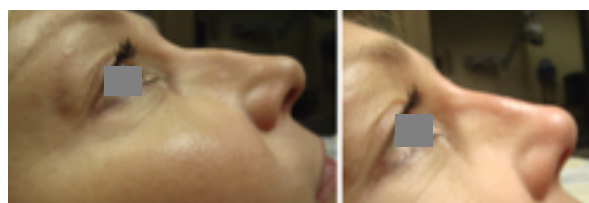


Fig. 4: Medical rhinoplasty after surgery.

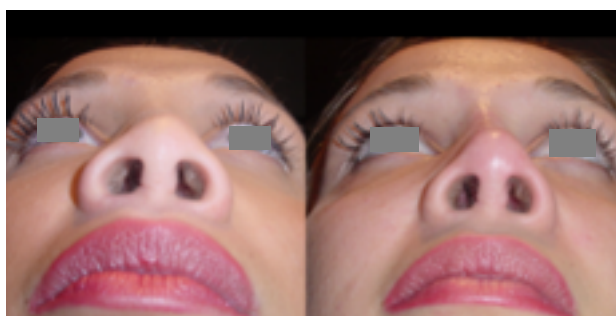

Fig. 5: Medical rhinoplasty after two surgeries.

Aesthetic and functional approach of rhinoplasty

The use of hyaluronic acid in the septal-triangular valve region is a way to counter the area's collapse occurring after surgical rhinoplasty. This technique is very interesting because of its simplicity; Following a xylocaine nafazoline local anesthesia, a direct transmucosal injection is performed. The patient immediately appreciates the benefits and guides us to the quantity of product to be injected (generally between 0.1 and 0.3 cc by side). This injection «replaces» the surgical use of spreader grafts, and has to be renewed once or twice a year to stabilize the result. This treatment can be associated with an aesthetic procedure at the same time.

COMPLICATIONS OF MEDICAL RHINOPLASTY WITH FILLERS

These can be related to the injection site. The literature reports minor complications such as ecchymosis, granulomas, oedema and allergic reactions [8, 9]. Management is the same as for the rest of the face (cold application, extrusion, vitamin K ointment, and hyaluronidase). Major complications have also been reported: Skin necrosis and visual loss.

Skin necrosis can result from local ischemia when injections are too superficial (localized necrosis), or from distal embolization (extensive necrosis). These local ischemic events can be found in cases of tip injection, nasal dorsum injection, glabella injection [10]. Embolic necrosis events can be related to glabella and nasolabial fold injections [11]. Skin ischemia with necrosis usually evolves positively with moderate scarring, and does not contraindicate further injection procedures. Initial symptoms can be a simultaneous local blanching, followed by blue discoloration of the skin, then necrosis. The patients suffer from immediate and abnormal pain at the injection site. Infectious complications can occur and has been described after hyaluronic acid injection [12].

Embolic complications with loss of vision are usually related to hyaluronic acid injections and lipofilling in the glabella or nasolabial fold [13]. Of the various hypotheses proposed in terms of physiopathology, retrograde embolization is the main accepted theory; direct injection in the dorsal nasal artery or the supra-trochlear artery results in occlusion of the ophthalmic artery. Tansatit et al [14] cadaveric work demonstrates the communicating vascular network between the face and the retinal artery, confirming the embolization hypothesis. Angiographic findings after visual loss following dermal facial filler injections are specifically related to retinal ischemia: Diffuse with distal occlusion when injecting hyaluronic acid or proximal occlusion with retrograde ischemia with lipofilling [15]. This complication is dreadful, with almost no recovery. Initial clinical signs are sharp abnormal retro-bulbar pain with immediate visual loss and sometimes ophthalmoplegia.

There is no management consensus for these complications. Skin necrosis can be treated with local injection of hyaluronidase, Lovenox 0.4 mL, systemic steroids (1 mg/kg/day for 3 days), and sometimes hyperbaric oxygen therapy for wound healing.

No efficient treatment is available for visual loss after dermal facial fillers injections [16]. All intended treatment shows no efficacy after visual loss has occurred (hyaluronidase injection or arterial thrombolysis). However, if intolerable pain appears after injection,

hyaluronidase and Lovenox 0.4 mL can be injected at the injection site, as a means of preventing loss of vision.

CONCLUSION

Medical rhinoplasty is efficient with beautiful and stable results. An artistic approach is essential to achieve this technique and to adapt the treatment to each individual case.

Bibliography

1. BRACCINI F, DOHAN EHRENFEST DM. Advantages of combined therapies in cosmetic medicine for face ageing: Botulinum toxin filler and mesotherapy. *REV LARYNGOL OTOL RHINOL (BORD)*. 2010;131(2):89-95.
2. REDAELLI A, BRACCINI F. Medical Rhinoplasty. Basic principles and clinical practice. *Ed. OEO Firenze* 2010.
3. BRACCINI F, DOHAN EHRENFEST DM. Medical rhinoplasty: Rationale for atraumatic nasal modelling using botulinum toxin and fillers. *REV LARYNGOL OTOL RHINOL (BORD)*. 2008;129(4-5):233-8.
4. BRACCINI F, PORTA P, THOMASSIN JM. Mini-rhinoplasty. *REV LARYNGOL OTOL RHINOL (BORD)*. 2006;127,1:15-20.
5. BRACCINI F, BERROS P, BELHAOUARI L. Botulinum toxin, description and clinical applications in the treatment of the face wrinkles. *REV LARYNGOL OTOL RHINOL (BORD)*. 2006;127(1-2):105-11.
6. REDAELLI A. Medical rhinoplasty with hyaluronic acid and botulinum toxin A: A very simple and quite effective technique. *JOURNAL OF COSMETIC DERMATOLOGY*. 2008;7:210-220.
7. BRACCINI F. In: *Anatomy and volumising injections. The nose. Fillers and rhinoplasty. E2e Medical publishing. Master Collection* 2. 2013:105-122.
8. FUNT D, PAVICIC T. Dermal fillers in aesthetics: An overview of adverse events and treatment approaches. *CLIN COSMET INVESTIG DERMATOL*. 2013 Dec 12;6:295-316.
9. DE BOULLE K, HEYDENRYCH I. Patient factors influencing dermal filler complications: Prevention, assessment, and treatment. *CLIN COSMET INVESTIG DERMATOL*. 2015 Apr;15,8:205-14.
10. HONART JF, DURON JB, MAZOUZ DORVAL S, RAUSKY J, REVOL M. A case of nasal tip necrosis after hyaluronic acid injection. *ANN CHIR PLAST ESTHET*. 2013 Dec;58(6):676-9.
11. CHEN Q, LIU Y, FAN D. Serious Vascular Complications after Nonsurgical Rhinoplasty: A Case Report. *PLAST RECONSTR SURG GLOB OPEN*. 2016 APR 21;4(4):E683.
12. CHADER H, BOSCH R, HERSANT B, LANGE F, HERMEZIU O, et al. Infectious cellulitis of the face complicating injection for esthetic nasolabial sulcus by hyaluronic acid: Report of seven cases. *ANN CHIR PLAST ESTHET*. 2013 Dec;58(6):680-3.
13. CARRUTHERS JD, FAGIEN S, ROHRICH RJ, WEINKLE S, CARRUTHERS A. Blindness caused by cosmetic filler injection: A review of cause and therapy. *PLAST RECONSTR SURG*. 2014 Dec;134(6):1197-201.
14. TANSATIT T, MOON HJ, APINUNTRUM P, PHETUDOM T. Verification of embolic channel causing blindness following filler injection. *AESTH PLAST SURG*. 2015;39:154-161.
15. KIM YK, JUNG C, WOO SJ, PARK KH. Cerebral angiographic findings of cosmetic facial filler-related ophthalmic and retinal. *J KOREAN MED SCI*. 2015 Dec;30(12):1847-55.
16. KIM A, KIM SH, KIM HJ, YANG HK, HWANG JM, KIM JS. Ophthalmoplegia as a complication of cosmetic facial filler injection. *ACTA OPHTHALMOL*. 2016 Aug;94(5):E377-9.